


Atrophic mandible fracture approach by load-bearing system: case report

Abordagem de fratura de mandíbula atrófica por sistema do tipo carga suportada: relato de caso

Albert da Paixão Silva ^{1*}, Alejandro Favio Estrada Michel ², Elias Almeida dos Santos ², Rafael Drummond Rodrigues ², Ravy Silva Carvalho ³

¹State University of Southwestern Bahia– UESB, Jequié, BA, Brazil.

²Bucomaxillofacial Surgery and Traumatology Service of the Federal University of Bahia and Irmã Dulce Social Works, Salvador, BA, Brazil.

³Bucomaxillofacial Surgery and Traumatology Service of the Hospital Geral do Estado, Salvador, BA, Brazil.

*albert_paixaoodonto@hotmail.com

ABSTRACT

Mandible fractures are the most frequent in the maxillofacial complex. Due to weakness and impaired reflexes, 10.1% to 56% of affected individuals are elderly. Thus, this study aimed to report a case report of a mandibular symphysis fracture in a total edentulous patient with an atrophic mandible treated through open surgery with a load-bearing device, demonstrating the management and characteristics relevant to this treatment. The 59-year-old male patient, melanoderma, attended the Oral and Maxillofacial Surgery and Traumatology Service of the General Hospital of the State, Bahia, after being a victim of a motorcycle accident, causing trauma to the face. The physical examination revealed, among other clinical signs, unstable maxilla and atypical mobility when manipulating the mandible. On imaging, there were signs suggestive of fracture of the mandibular symphysis, nasal bones, orbital zygomaticomaxillary complex, and Le Fort I maxillary fracture. A surgical approach allowed reduction and rigid internal fixation with a plate and 2.4mm system screws, while the middle third fractures followed a conservative treatment line. In the postoperative follow-up, there was an adequate fracture reduction and no signs of displacement of the fractured stumps. Furthermore, the patient had a satisfactory clinical recovery. In the literature, there is no consensus on the surgical approach and treatment of atrophic mandible fractures except by use of rigid fixation systems by load-bearing devices proved to be an effective alternative for fracture stabilization and consolidation in cases of mandibular atrophy as demonstrated in this work.

Keywords: Atrophy. Fracture fixation. Edentulous jaw.

RESUMO

As fraturas de mandíbula são as mais frequentes no complexo maxilofacial. Em razão da fraqueza e dos reflexos prejudicados, de 10,1% a 56% dos indivíduos acometidos são idosos. Assim, este estudo teve como objetivo reportar um relato de caso de fratura de sínfise mandibular em um paciente edêntulo total, apresentando mandíbula atrófica, tratado por meio de cirurgia aberta com dispositivo *load-bearing*, demonstrando o manejo e características pertinentes a esse tratamento. O paciente de 59 anos de idade, melanoderma, sexo masculino, compareceu ao serviço de Cirurgia e Traumatologia Bucomaxilofacial do Hospital Geral do Estado, Bahia, após ter sido vítima de acidente motociclístico, causando trauma na face. Ao exame físico foi verificado, dentre outros sinais clínicos, maxila instável e mobilidade atípica à manipulação da mandíbula. Ao exame de imagem, notou-se sinais sugestivos de fratura de sínfise mandibular, ossos próprios do nariz, complexo orbito-zigomático-maxilar e fratura maxilar do tipo Le Fort I. Foi realizada abordagem cirúrgica para redução e fixação interna rígida com uma placa e parafusos do sistema 2.4mm. Enquanto as fraturas do terço médio seguiram uma linha de tratamento conservadora. No acompanhamento pós-operatório, observou-se a fratura adequadamente reduzida e ausência de sinais de deslocamento dos cotos fraturados. Ademais, o paciente apresentou satisfatória recuperação clínica. Na literatura não existe consenso sobre a abordagem cirúrgica e tratamento de fraturas de mandíbulas atróficas, todavia, conforme demonstrado neste trabalho, a utilização de sistemas de fixação rígida por dispositivos *load-bearing*, demonstrou ser uma alternativa eficaz para a estabilização e consolidação de fraturas em casos de atrofia mandibular.

Palavras-chave: Atrofia. Fixação de fratura. Mandíbula edêntula.

INTRODUCTION

Facial trauma results from forces changing the anatomy and function in the upper, middle, and lower thirds of an individual's face, resulting in injuries to both soft and bone tissue (Camino, Moraes, Landes & Luz, 2017). The mandible is the only mobile bone of the face. It is related to some of the main functions of the stomatognathic system, such as phonation, mastication, dental occlusion, and swallowing as well as aesthetic function. In addition, it is one of the bones most affected by facial trauma. It can be explained by its anatomy and topography, with a more anterior projection, which makes it one of the most exposed bones from face to trauma (Camino et al., 2017; Zamboni et al., 2017).

Mandible fractures are the most common in the maxillofacial complex, occurring in about 42.5% of facial trauma. Therefore, they represent a crucial cause of morbidity and costs to health systems (Zamboni et al., 2017). In Brazil, motorcycle accidents and firearm aggression are the primary causes of facial trauma, especially in the northeastern part of the country, varying according to social, geographic, and socioeconomic characteristics (Pita et al., 2018).

The diagnosis of these fractures is clinical, through a well-executed physical examination and complementary exams. Two-dimensional radiographs and CT scans of the face are essential, as they ensure a better assessment of the fracture and its extensions (Rodrigues, Uchôa, Torres, Dib & Oliveira, 2020). Also, according to the same authors, the physical examination should observe both main mandibular fractures signs and symptoms. These signs might be atypical mobility when handling the mandible, occlusal dystopia, limited mouth opening, localized edema, sublingual ecchymosis, asymmetries, pain, and paresthesia.

The ideal approach to the treatment of mandibular fractures is still controversial. This treatment comprises the reduction, fixation, and fractured bone stumps immobilization. In addition, some lesion factors and characteristics must be considered such as displacement and comminution of fractured fragments, muscle action, malocclusions, patient age, and surgeon skill (McNamara, Findlay, O'Rourke & Batstone, 2016). One of the treatment options, in a bloody way, is rigid internal fixation using load-sharing and load-bearing fixation devices, with specific indications for each of them (McNamara et al., 2016; Rodrigues et al., 2020).

Insufficient stability to support all the functional loads applied through the fracture characterized turns load-sharing devices more delicate, sharing these generated loads with the fractured bone. While load-bearing devices consist of tools with sufficient strength and rigidity to support all the functional loads of the mandible, avoiding displacements and instabilities in fractures (Rodrigues et al., 2018; Oliveira et al., 2021).

Therefore, this work aims to report a clinical case of mandibular symphysis fracture in a total edentulous patient with an atrophic mandible treated through open surgery with a 2.4 mm load-bearing system reconstruction plate, in addition to demonstrating the management and characteristics relevant to this treatment.

CLINICAL CASE REPORT

A 59-year-old melanoderma male patient with good general health status attended the Oral and Maxillofacial Surgery and Traumatology Service of the General Hospital of the State (HGE) Bahia after a motorcycle accident, causing facial trauma.

The maxillofacial physical examination showed preserved bone contours in the upper third of the face, extrinsic ocular motricity and bilaterally referred visual acuity, hyposphagma of the left eye, left infraorbital ridge step, ecchymosis, and periorbital edema in the left eye.

In addition, excoriations were observed on the right hemiface, in the regions of the chin, upper lip, nasal dorsum, glabella, and temporalis. Stable bones of the nose (BN), unstable maxilla with crepitus, and ecchymosis in the soft palate bilaterally were noticed still during the physical examination. In the lower third of the face, there was an ecchymosis on the upper and lower labial

mucosa bilaterally and on the floor of the mouth; atypical mobility on mandibular manipulation in the symphyseal region, and regular mouth opening. Furthermore, this is a total edentulous patient in both arches, referring to the full use of both dentures in the upper and lower arches but not wearing them at the time of the examination (Figures 1 and 2).

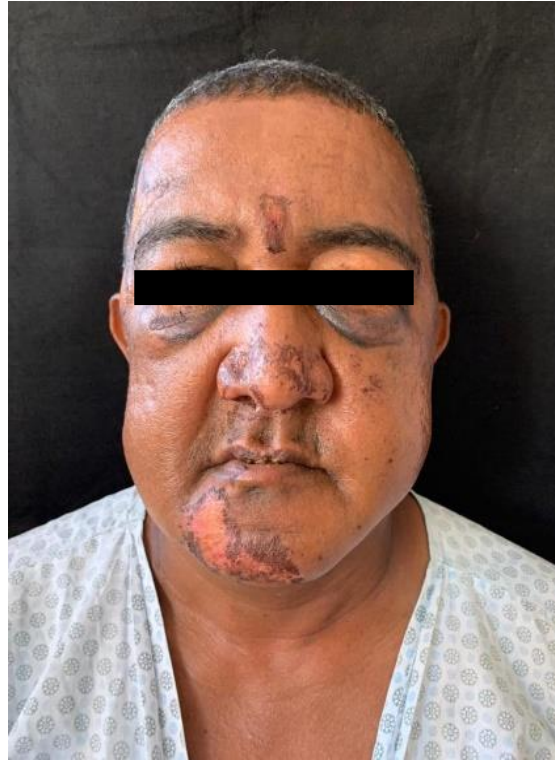

Figure 1. Frontal view of the patient's preoperative period.
Source: The authors.

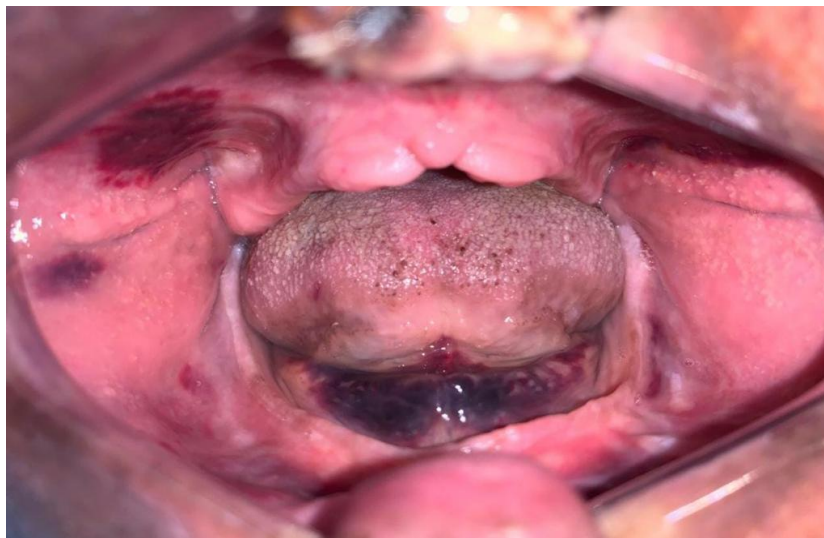

Figure 2. Intraoral image of the patient in the preoperative period.
Source: The authors.

The imaging exam – computed tomography of the face – showed signs suggestive of mandible fracture in the symphysis region, BN, left orbital zygomaticomaxillary complex (OZMC), and Le Fort I maxillary fracture (Figure 3).

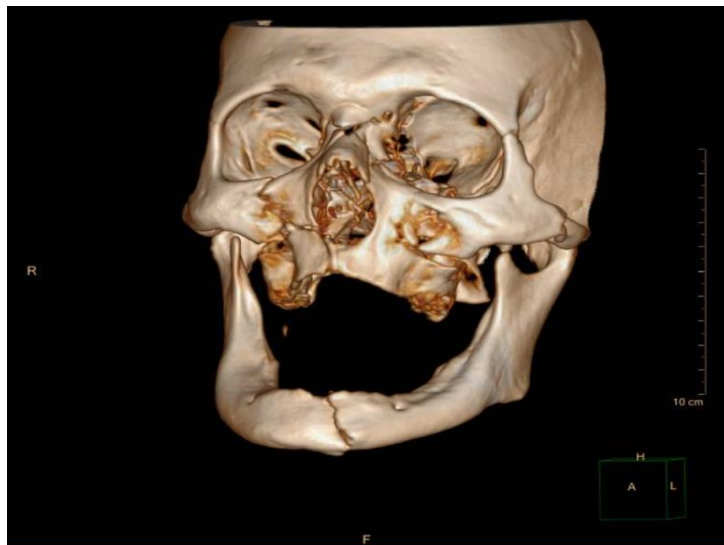

Figure 3. 3D reconstruction of the patient's preoperative face tomography, showing the fracture line in the mandibular symphysis.

Source: The authors.

After the clinical evaluations and imaging tests of the fractures, the choice of approach was the most conservative of the fractures found in the middle third of the patient's face, such as BN, OZMC, and Le Fort I fractures. They did not present functional or aesthetic impairment to the patient, even so, a surgical approach came to pass for the mandibular fracture for reduction and rigid internal fixation from the load-bearing system with a plate and screws of the 2.4 mm system – load-bearing.

The procedure was performed with the patient in the supine position, under general anesthesia, with nasotracheal intubation. After patient antisepsis with chlorhexidine digluconate and apposition of the operative fields, the installation of an oropharyngeal plug and subcutaneous anesthetic infiltration with 0.5% bupivacaine with 1:200,000 epinephrine occurred in the submandibular region.

Extraoral, submandibular access occurred to approach the mandibular symphysis, with fractured bone stumps exposure. The fracture lines were stabilized and the mandibular anatomical contour was reestablished through reduction. Fracture fixation happened with a 2.4 system load-bearing device plate and screws (Figure 4). Next, copious irrigation with 0.9% saline solution was performed, and the surgical access was synthesized in layers, with 4-0 vicryl resorbable thread for the muscular planes and 5-0 nylon for the cutaneous plane.

In the postoperative control radiographs on the second day after the approach (posteroanterior and axial radiographs of the face), it was possible to observe the occurrence of balanced repositioned fragments with the proper positioning of the fixation materials and mandibular framework reestablished. In the immediate postoperative period, the patient evolved without significant edema, with no loss or motor skills decrease and facial expression. Cefazolin 1g of 6/06 hours intravenously for prophylactic use was administered as drug therapy. The patient was discharged from the hospital on the third postoperative day and referred for outpatient follow-up.

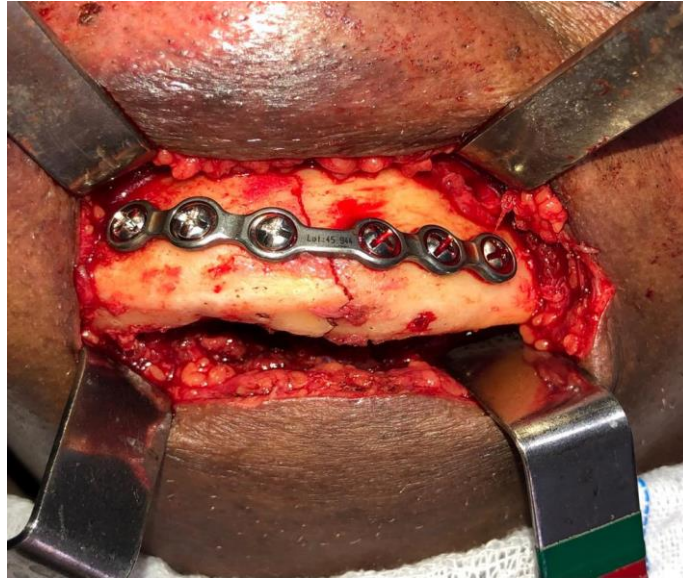


Figure 4. Adaptation and rigid internal fixation of the 2.4 mm system plate (load bearing) intraoperatively.
Source: The authors.

During this period, the patient had neither spontaneous pain complaints nor an extraoral suture in position, no signs of inflammation, edema compatible with the surgical procedure, and regular mouth opening. On return 30 days after surgery, the patient had a panoramic postoperative control radiograph, which showed osteosynthesis material in position (Figure 5) and presented good clinical recovery (Figure 6).

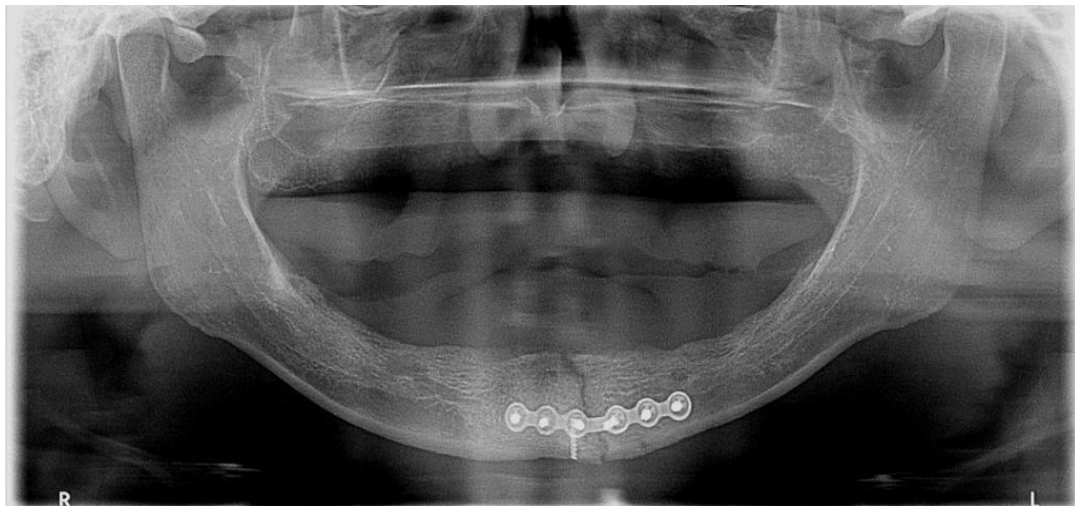


Figure 5. 30-day postoperative control panoramic radiograph, showing osteosynthesis material in position.
Source: The authors.

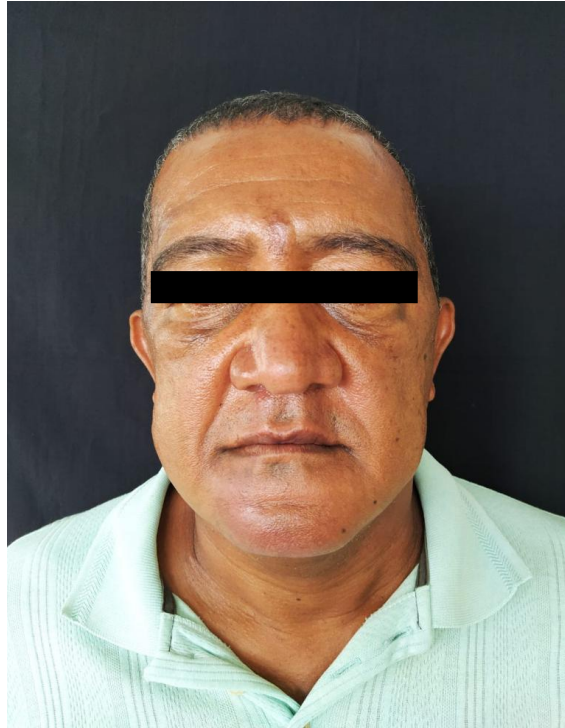

Figure 6. Front view of the patient 30 days after surgery, showing good recovery.
Source: The authors.

DISCUSSION

Mandibular atrophy is a problem that arises due to the loss of dental elements followed by resorption of the alveolar process of the mandible, making it more susceptible to fractures (Ellis & Price, 2008). Therefore, it is a common condition in elderly individuals (Coll et al., 2020).

The atrophic mandible arose when the thickness of the residual mandibular bone is less than 15 mm, making it less resistant to trauma and more vulnerable to fractures due to the decrease in this bone volume (Shokri, Misch, Ducic & Sokoya, 2019). However, other authors (Ellis & Price, 2008; Castro-Núñez, Cunningham & Van Sickels, 2017; Brucoli et al., 2020) already consider an atrophic mandible when the amount of residual bone is less than 20 mm. Values below 10 mm are extremely atrophic once the area with the highest fracture incidences is the mandibular body region. However, in the present case, the area affected by the fracture was the mandibular symphysis. Understanding the mechanics of trauma is essential to investigate other regions of lower bone strength with the possibility of fracture through the dissipation of forces, such as the mandibular condyle region.

Maxillofacial trauma, in some cases, can incur irreversible physical sequelae, as well as severe psychosocial impairment to the individual (Marinho et al., 2015). As a rule, mandible fractures can progress to deformities in the patient's stomatognathic system when not properly treated. This can result from dislocations, loss of bone segments, and changes in dental occlusion or temporomandibular joint (Andrade et al., 2000).

As already demonstrated in the literature (Rodrigues et al., 2020) and evidenced by the present case, a more accurate and precise diagnosis is essential for the proper location and treatment of the fracture. Therefore, a thorough physical examination is necessary, paying attention to the main signs and symptoms associated with these fractures, such as, for example, atypical mobility with jaw manipulation, edema and ecchymosis, facial asymmetry, limited mouth opening, occlusal dystopia, pain, and paresthesia.

In addition, the association in the diagnosis of complementary imaging tests is crucial. CT scans of the face are more accurate in determining the extent and providing better visualization of the

fracture. This exam allows a three-dimensional assessment of the fracture, with less overlapping of anatomical structures in the image (Silva et al., 2020).

The surgical treatment of maxillofacial fractures aims to restore function, aesthetics, and regional anatomy with the aid of plates and screws for this specific purpose (Bouchard & Mansouri, 2017). BN, COZM on the left, and Le Fort I fractures followed the conservative treatment line because the patient did not have any clinical and functional repercussions caused by the fractures and because they were aligned fractures, which did not justify a surgical approach.

Hayward and Scott (1993) reported that patient age, fracture location, and degree of displacement are important factors to consider when choosing a therapy. According to the literature, the choice of treatment for some fractures, whether conservative or surgical, depends mainly on the communication and its degree of displacement, so that satisfactory results can be obtained (Pereira & Shinohara, 2000; Dingman & Natvig, 2004; Swinson, Amin, Nair, Lloyd & Ayliffe, 2004). That is, fractures without displacement, or with minimal displacement and without aesthetic or functional impairment, can be treated conservatively (Starch-Jensen; Linnebjerg & Jensen, 2018).

According to Teles, Cruz, Parreira, Sousa, and Curvina (2016), therapeutic success is determined by the recovery of facial functions. As reported in the present case, the conservative approach to these fractures achieved this objective, since there was a proper aesthetic and functional recovery of the patient.

Although the surgical approach is indicated for mandibular fractures with displacement between the bone stumps, in cases of an atrophic mandible fracture, its treatment is still controversial (Rodrigues et al., 2018). This is a major challenge for maxillofacial traumatology, given the physiological, morphological, and biomechanical characteristics of the edentulous mandible (Shokri et al., 2019).

As in the case reported above, the treatment of elderly patients can be challenging, due to the morpho-physiological characteristics of the atrophic mandible, such as bone quantity and quality. Other factors such as the contact area of the fractured segments, inadequate blood supply, and possible systemic changes present in the patient contribute to a complex treatment approach (Bradley, 1972; Marciani, 2001).

Rigid internal fixation systems for the treatment of maxillofacial fractures ensure the approximation of the fractured stumps and their immobility, which are essential for adequate healing (Bouchard & Mansouri, 2017). Load-sharing devices consist of screws and miniplates from 1.5 mm to 2 mm systems, generally indicated in cases of linear fractures and with bone fragments solid enough to support part of the functional loads. On the other hand, load-bearing is represented by plates and screws of the 2.4 mm or 2.7 mm systems and is primarily indicated for comminuted fractures cases or fractures with a large break in bone continuity (Rodrigues et al., 2018; Oliveira et al., 2021).

Some techniques described in the literature used for this approach are the use of splints, external fixators, steel wires, and stable internal fixation (Bruce & Strachan, 1976; Bruce & Ellis, 1993). The choice of the most appropriate therapeutic approach depends, among other factors, on the severity of the mandibular atrophy. That is, the more extensive the atrophic condition, the more rigid internal fixation is indicated (Wittwer, Adeyemo, Turhani & Ploder, 2006). Given this, based also on recommendations from the AO Foundation (Schilli, Stoll, Bähr & Prein, 1998) and as defended by Bruce and Ellis (1993), it was decided to approach the patient in the present case with fixation systems of the load-supported type with 2.4mm reconstruction plates. Furthermore, according to Marciani (2001), the quality and quantity of bone in the atrophic mandible present the need for reconstructions with stronger osteosynthesis in fracture cases.

Despite authors such as Choi, Huh, Suh, and Kim (2005) considering one of the recommended techniques for this approach, the use of fixation with two miniplates, allowing adequate stability at the fracture site. In contrast, Iatrou, Samaras, and Lygidakis (1998), in a study that did not consider the degree of mandibular atrophy of the patient, concluded that a single Champy miniplate would be a reliable and sufficient method to stabilize these mandibular fractures in edentulous patients.

However, other authors support that in cases of the atrophic mandible, the use of shared load systems, that is, plates and screws of smaller size and rigidity, is not the most appropriate, because this type of osteosynthesis often results in failures in the fixation, infections and pseudarthrosis (Bruce & Ellis, 1993; Luhr, Reidick & Merten, 1996; Lima et al., 2014; Pereira et al., 2017).

In the case reported, it was decided to approach the patient through extraoral access, aiming to offer a better view of the fracture region in a wide and direct way, favoring the adaptation of the rigid fixation system (Oliveira et al., 2021). Thus, a 2.4 mm system plate was used for fracture reduction and fixation, given its ability to provide stable fixation (Oliveira et al., 2021).

After the outpatient follow-up of the case, it was possible to observe the anatomical and functional restoration of the mandibular framework of this patient, and this type of approach and fixation proved to be quite efficient in cases of mandibular atrophy.

CONCLUSION

The treatment of atrophic mandibular fractures is always a challenge for the routine of Oral and Maxillofacial Surgeons. Thus, it is essential to understand the trauma process and the etiology so that the most appropriate surgical approach and method can be defined for each case, thus favoring a higher success rate in these treatments. Although there is no consensus in the literature for the surgical approach and treatment of fractures of atrophic mandibles, as demonstrated in the present study, the use of rigid fixation systems by load-bearing devices proved to be an effective alternative for stabilization and consolidation. of fractures in cases of mandibular atrophy.

REFERENCES

- Andrade, E. F. F., Fadul, R., Jr., Azevedo, R. A., Rocha, M. A., d Santos, R., Toledo, S. R., ... & Ferreira, L. M. (2000). Mandibular fractures: analysis of 166 cases. *Revista da Associação Médica Brasileira*, 46(3), pp. 272-276.
- Bouchard, C., & Mansouri, M. (2017). Open reduction with internal fixation of mandibular angle fractures: a retrospective study. *Journal of the Canadian Dental Association*, 83(3), pp. 1-6.
- Bradley, J. C. (1972). Age changes in the vascular supply of the mandible. *Brazilian Dental Journal*, 132(4), pp. 142-4.
- Bruce, R. A., & Strachan, D. S. (1976). Fractures of the edentulous mandible: the Chalmers J. Lyons Academy study. *Journal of Oral and Maxillofacial Surgery*, 34(11), pp. 973-9.
- Bruce, R. A., & Ellis, E. (1993). The second Chalmers J. Lyons Academy study of fractures of edentulous mandible. *Journal of Oral and Maxillofacial Surgery*, 51(8), pp. 904-11.
- Brucoli, M., Boffano, P., Romeo, I., Corio, C., Benech, A., Ruslin, M., ... & Starch-Jensen, T. (2020). Surgical management of unilateral body fractures of the edentulous atrophic mandible. *Oral and Maxillofacial Surgery*, 24(1), pp. 65-71.
- Camino, R., Jr., Moraes, R. B., Landes, C., & Luz, J. G. C. (2017). Comparison of a 2.0-mm locking system with conventional 2.0-and 2.4-mm systems in the treatment of mandibular fractures: a randomized controlled trial. *Oral and Maxillofacial Surgery*, 21(3), pp. 327-334.
- Castro-Núñez, J., Cunningham, L. L., & Van Sickels, J. E. (2017). A historical perspective with current opinion on the management of atrophic mandibular fractures. *Oral Surgery, Oral Medicine, Oral Pathology and Oral Radiology*, 124(6), e276-e282.

- Choi, B. H., Huh, J. Y., Suh, C. H., & Kim, K. N. (2005). An in vitro evaluation of miniplate fixation techniques for fractures of the atrophic edentulous mandible. *International Journal of Oral and Maxillofacial Surgery*, 34(2), pp. 174-7.
- Coll, P. P., Lindsay, A., Meng, J., Gopalakrishna, A., Raghavendra, S., Bysani, P., & O'Brien, D. (2020). The prevention of infections in older adults: oral health. *Journal of the American Geriatrics Society*, 68(2), pp. 411-416.
- Dingman, R. O., & Nativig, P. (2004). *Cirurgia das fraturas faciais*. 3. ed. São Paulo: Santos.
- Ellis III, E., & Price, C. (2008). Treatment protocol for fractures of the atrophic mandible. *Journal of oral and maxillofacial surgery*, 66(3), pp. 421-435.
- Hayward, J., & Scott, R. A. (1993). Fractures of mandibular condyle. *Journal of oral and Maxillofacial Surgery*. 1: pp. 57-61.
- Iatrou, I., Samaras, C., & Lygidakis, N. T. (1998). Miniplate ostesynthesis for fractures of the edentulous mandible: a clinical study, 1989-1996. *Journal of Cranio-Maxillofacial Surgery*, 26, 400.
- Luhr, H.G., Reidick, T., & Merten, H. A. (1996). Results of treatment of fractures of the atrophic edentulous mandible by compression plating: a retrospective evaluation of 84 consecutive cases. *Journal of oral and Maxillofacial Surgery*, 54(3), pp. 250-4.
- Lima, L. B., Oliveira, M. T. F., Batista, J. D., Rocha, F. S., da Silva, M. C. P., & Silva, C. J. (2014). Tratamento cirúrgico de fratura em mandíbula atrófica. *Revista Odontológica do Brasil Central*, 23(67).
- Marciani, R. D. (2001). Invasive management of the fractured atrophic edentulous mandible. *Journal of Oral and Maxillofacial Surgery*, 59(7), pp. 792-5.
- Marinho, K., Guevara, H. A. G., Piva, F. H., Rocha, B., Gonzalez, D., & Leandro, L. F. L. (2015). Epidemiological analysis of mandibular fractures treated in Sao Paulo, Brazil. *Revista Española de Cirugía Oral y Maxilofacial*, 37(4), pp. 175-181.
- McNamara, Z., Findlay, G., O'Rourke, P., & Batstone, M. (2016). Removal versus retention of asymptomatic third molars in mandibular angle fractures: a randomized controlled trial. *International Journal of Oral and Maxillofacial Surgery*, 45(5), pp. 571-574.
- Starch-Jensen, T., Linnebjerg, L. B., & Jensen, J. D. (2018). Treatment of zygomatic complex fractures with surgical or nonsurgical intervention: a retrospective study. *The Open Dentistry Journal*, 12, 377.
- Oliveira, G. P., Carvalho, M. M. M. D., Rodrigues, R. D., Barbosa, D. M. D. O., Borges, E. F. D. D., & Seixas, A. M. (2021). Acesso extraoral para tratamento cirúrgico de fratura de mandíbula atrófica: relato de caso. *Revista Odontológica de Araçatuba* (Impr.), pp. 42-46.
- Pereira, A. C. J., & Shinohara, H. (2000). Fratura simples do arco zigomático dispensando aparato de proteção. *Revista da APCD*, 36(1), p. 12.
- Pereira, R. S., Bonardi, J. P., da Silva, J. R., Mourão, C. F. D. A. B., Júnior, P. R. B., & Magacho, L. F. (2017). Tratamento cirúrgico da fratura de mandíbula atrófica pela técnica AO: relato de caso. *Archives of Health Investigation*, 6(3).

- Pita Neto, I.C., Franco, J.M.P.L., Araujo Junior, J.L., Santana, M.D.R., Abreu, L.C., Bezerra, I.M.P., ... & Rodrigues L.M.R. (2018). Factors associated with the complexity of facial trauma. *Journal of Craniofacial Surgery*, 29(6), e562-e566.
- Rodrigues, É. R., Uchôa, C. P., Torres, L. H. S., Dib, C. F. L. B., & de Oliveira, E. D. (2020). Fixação funcionalmente estável no tratamento de sequela de fratura cominutiva de mandíbula por PAF. *Revista da Faculdade de Odontologia-UPF*, 25(2), pp. 247-253.
- Rodrigues, R. D., Quintas, P. H., da Silva Barreto, L., Costa, C. F. B., Silva, L. O. R., & Aguiar, J. F. (2018). Manejo cirúrgico de fratura de mandíbula: relato de caso. *Revista da Faculdade de Odontologia-UPF*, 23(3), pp. 343-347.
- Shokri, T., Misch, E., Ducic, Y., & Sokoya, M. (2019). Management of Complex Mandible Fractures. *Facial Plastic Surgery*, 35(06), pp. 602-606.
- Silva, R. F., Pereira, R. V. S., Silva, J. D. Â. A., de Luna Campos, G. J., da Costa, M. C. F., & de Araújo, F. F. (2020). Tratamento de fratura de mandíbula atrófica: prototipagem como ferramenta no planejamento cirúrgico. *Research, Society and Development*, 9(9), e796997986-e796997986.
- Swinson, B., Amin, M., Nair, P., Lloyd, T., & Ayliffe, P. (2004). Isolated bilateral orbital floor fractures: a series of 3 cases. *Journal of oral and maxillofacial surgery*, 62(11), pp. 1431-1435.
- Schilli, W., Stoll, P., Bähr, W., & Prein, J. (1998). Mandibular fractures. In: Prein J ed. Manual of internal fixation in the cranio-facial skeleton: Techniques recommended by the AO/ ASIF Maxillofacial Group. New York: Springer. 87.
- Teles, I. C. M., Cruz, J. A., Parreira, D. R., Sousa, G. H. C., & Curvina, M. M. G. (2016). Fratura panfacial: um relato de caso. *Revista de Medicina e Saúde de Brasília*, 5(3), pp. 222-8.
- Zamboni, R. A., Wagner, J. C. B., Volkweis, M. R., Gerhardt, E. L., Buchmann, E. M., & Bavaresco, C. S. (2017). Levantamento epidemiológico das fraturas de face do Serviço de Cirurgia e Traumatologia Bucomaxilofacial da Santa Casa de Misericórdia de Porto Alegre-RS. *Revista do Colégio Brasileiro de Cirurgiões*, 44, pp. 491-497.
- Wittwer, G., Adeyemo, W. L., Turhani, D., & Ploder, O. (2006). Treatment of atrophic mandibular fractures based on the degree of atrophy--experience with different plating systems: a retrospective study. *Journal of oral and Maxillofacial Surgery*, 64(2), pp. 230-234.