







Mandibular fracture in victim of domestic aggression: case report

Fratura mandibular em vítima de agressão domiciliar: relato de caso

Mariana Machado Mendes de Carvalho , Daiana Cristina Pereira Santana , Marcelo Oldack Silva , Rafael Drummond Rodrigues , Juliana Jorge Garcia *, Alexandre Martins Seixas 

Federal University of Bahia/Irmã Dulce Social Works, Bahia, BA, Brazil.

*jujubajorge@hotmail.com

ABSTRACT

As a consequence of its prominence on the face, the mandible is one of the bones most susceptible to fractures caused by different etiological agents. Currently, domestic violence has been a considerable factor in the appearance of facial injuries, which are mostly performed by partners of the victims. The aim of this study is to report a case of mandibular fracture caused by domestic violence. Female patient, victim of domestic aggression, attended at the Maxillofacial Service, in Bahia, with extensive submandibular hematoma, facial asymmetry, pain during physical examination and presence of atypical mobility on mandibular manipulation. The Computed Tomography exam evidenced two fracture lines in the mandible. The patient was submitted to surgery for osteosynthesis, uneventfully. Considering that the face is an aesthetic region, manipulation in those structures is an aesthetic and functional challenge, requiring specialized care.

Keywords: Domestic violence. Facial injuries. Jaw. Maxillomandibular fractures.

RESUMO

Como consequência de sua proeminência na face, a mandíbula é um dos ossos mais susceptíveis a fraturas por diferentes agentes etiológicos. Atualmente, a violência doméstica tem sido um fator considerável no aparecimento de lesões faciais, as quais são praticadas em sua maioria pelos companheiros das vítimas. O objetivo deste estudo é relatar um caso de fratura mandibular decorrente de violência doméstica. Paciente do sexo feminino, vítima de agressão domiciliar, compareceu ao serviço de Cirurgia Bucomaxilofacial com extenso hematoma submandibular, assimetria facial, queixas algicas em face à palpação e presença de mobilidade atípica a manipulação mandibular. Ao exame de tomografia computadorizada observou-se dois traços de fratura em mandíbula e a paciente foi então submetida a cirurgia para osteossíntese, sem intercorrências. Tendo em vista que a face é uma região de grande visibilidade para os pacientes, é um grande desafio estético e funcional a manipulação de estruturas lesadas nessa região, sendo necessário um atendimento especializado.

Palavras-chave: Fraturas maxilomandibulares. Mandíbula. Traumatismos faciais. Violência doméstica.

INTRODUCTION

Facial traumas are responsible for injuries capable of causing functional and aesthetic changes in the structures that compose it. The mandible is the second most prevalent anatomical structure in facial fractures. This has a prevalence about 36 to 70% because it is a prominent bone (Boffano et al., 2015; Munante-Cardenas, Nunes & Passeri, 2015), being one of the types of fracture most commonly treated by the oral and maxillofacial surgeon (Gadicherla et al., 2016).

The etiology of fractures includes traffic accidents, physical aggression, use of weapons, domestic or sport accidents. The diagnosis of these fractures is clinical and has the help of imaging tests, such as radiographs or more detailed tests, such as computed tomography, which gives us a three-dimensional view of the case, making easy diagnosis and surgical planning, if necessary. The treatment is based on stabilization and, in some cases, immobilization of the fracture in the attempt to reestablish the prior occlusion to the trauma. It can be performed in an open or closed manner depending on the case (Barros et al., 2021).

Domestic violence can be defined as “deliberate physical abuse, repetitive in most times, performed by one family member against another”. It is one of the causes of injuries in various parts of the body, including the oral and maxillofacial region (Hashemi et al., 2011). Currently, it can be known through the term gender violence (Rezende, Araújo, Moraes, Santana & Radicchi, 2007; Araújo, 2012).

There is a tendency among professionals to relate domestic violence as a problem that concerns the sphere of public security and not the health care. Most health disciplines in undergraduate courses do not have the necessary education and training in aspects related to violence in their curricula, making health professionals unprepared to provide care that has a significant impact on victims' lives. However, violence is a problem that is on the rise and has become the focus of discussion in public health since the late 1980s and fits perfectly into the expanded concept of health, in which everything that threatens life is included in the universe of public health (Pereira, Rodrigues, Blois & Souza, 2019; Rezende et al., 2007).

In Brazil, physical violence is the most frequent type of violence that affects women and is identified as the first or second leading cause of facial injuries in this group. Injuries resulting from physical violence can reach the soft tissues and cause fractures in the maxillomandibular complex (Garcez et al., 2019).

The aim of this study is to report a case of mandibular fracture resulting from domestic violence and to point it out as an important etiological agent of facial fractures, besides to highlight the oral and maxillofacial surgeon as a professional of great importance in the aesthetic-functional rehabilitation of injured patients.

CASE REPORT

Female patient, with 33 years old, victim of physical aggression by her spouse, attended a hospital emergency service with trauma to the face.

The oral and maxillofacial physical examination showed an extensive submandibular hematoma (Figure 1) that was also present in the vestibule and floor of the mouth. Further, pain was noted on palpation and manipulation of the left mandibular body region and right angle, in addition to the presence of edema and atypical mobility to mandibular manipulation in these two regions and facial asymmetry (Figure 2). A computed tomography scan of the face was then requested, which showed two traces of fracture in the suspicious regions (Figure 3).

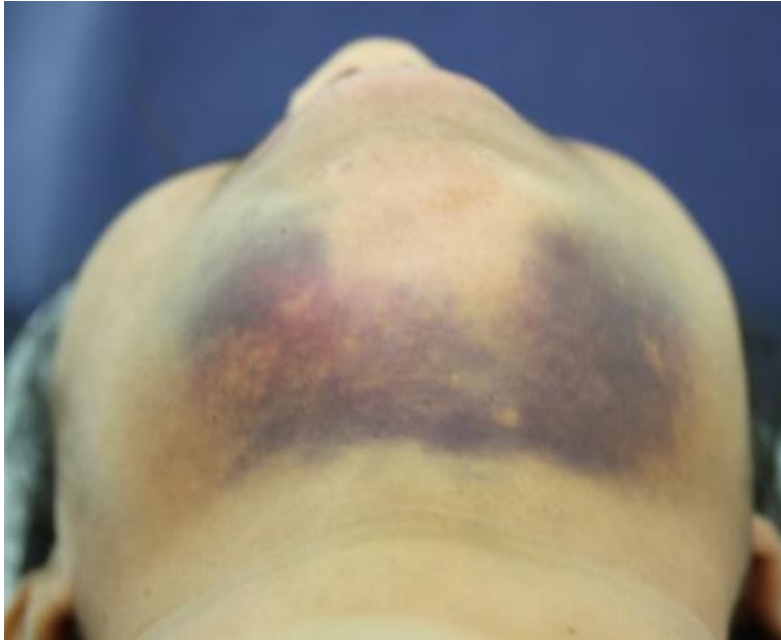


Figure 1. Extensive hematoma in the submandibular region.
Source: The authors.

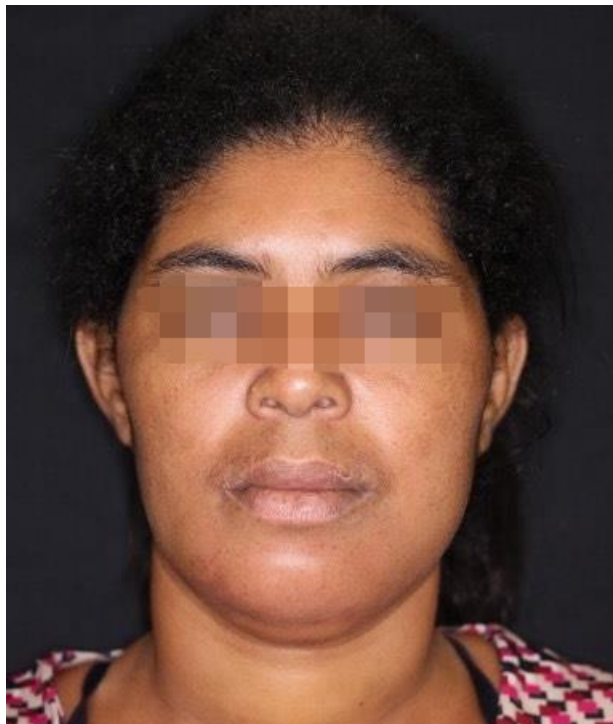

Figure 2. Initial photograph showing edema in the lower third of face on the left side and facial asymmetry.
Source: The authors.

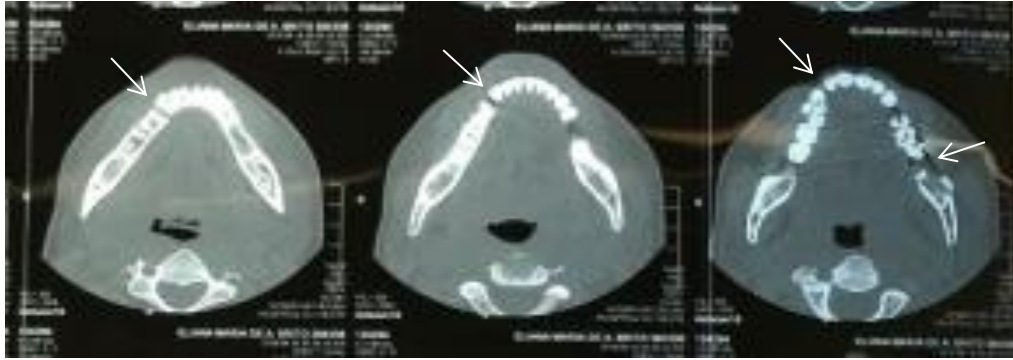

Figure 3. Axial section of computed tomography.
Source: The authors.

The initial procedure for this patient was to perform a maxillomandibular block (MMB) through the Ivy ligatures, an odontosynthesis that consists of installing steel wires in the premolar region in the upper and lower arch, joined together with the purpose of intermaxillary block and immobilization of the fracture, while she was waiting for availability to perform the surgery. Although there are other MMB options, such as Erich Bars, there were no resources available at the time for their installation and the fracture was well stabilized with the strapping performed. Five days after the MMB, osteosynthesis surgery for a complex fracture of the mandible was performed by intraoral access in the vestibule background in the region of teeth 41 to 36 to expose the mandible body fracture and in the retromolar region on the right side to access the angle fracture, which required bone fixation due to its unfavorable position. The muscular action of the masseter muscle displaced the fractured stumps. The mandibular body fracture was fixed with two 2.0 mm system plates, one with four holes in the tension zone and another with six holes in the compression zone (Figure 4), whereas the angle fracture was fixed with only one 2.0 mm system plate in the oblique line region, or tension zone, using the Champy technique (Figure 5).

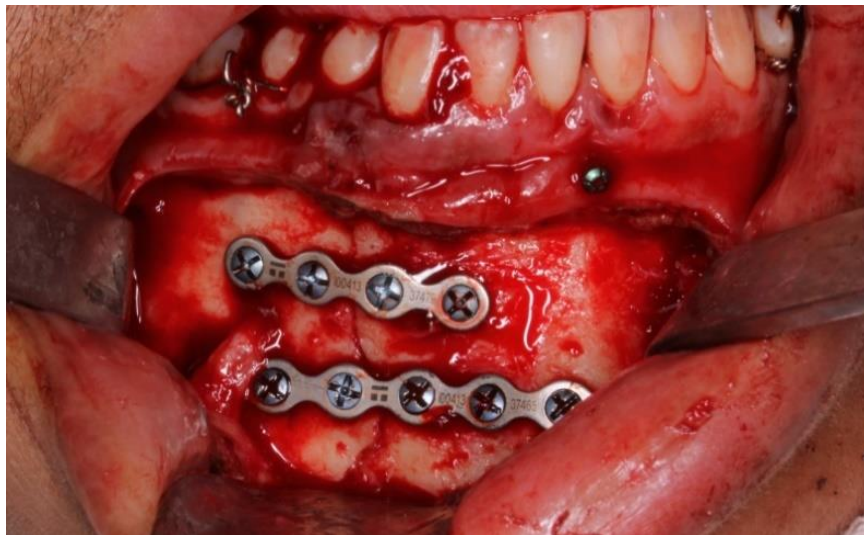


Figure 4. System 2.0 plates installed in the mandibular body on the right side.
Source: The authors.

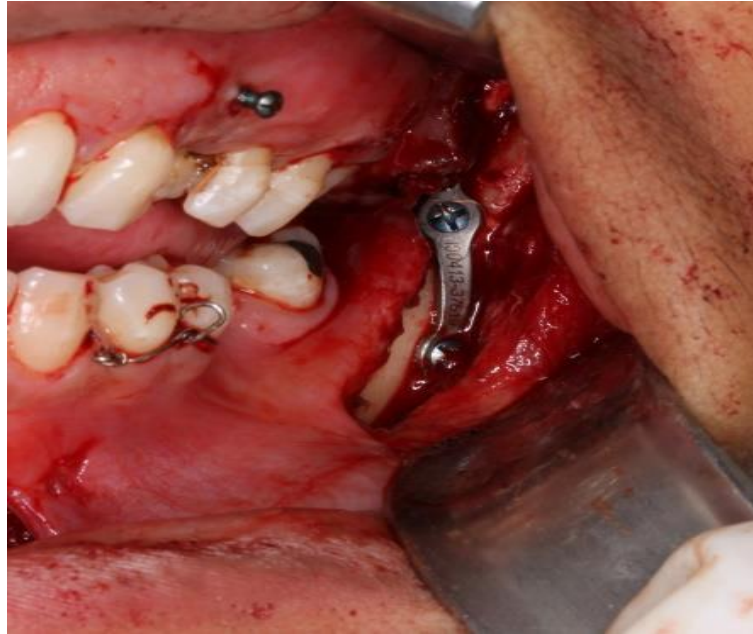


Figure 5. System 2.0 plate with spacer in the mandibular angle region on the right side.
Source: The authors.

The surgical procedure was uneventful. In the transsurgical procedure, we chose to maintain unit 38, so that it could be removed in a second surgical procedure due to the little displacement of the fracture and the fact that the unit was not in the line of that. After its completion, the patient continued with the MMB, this time with intermaxillary fixation screws during the first 30 postoperative days. A postoperative panoramic radiograph was performed (Figure 6) for follow-up and bone synthesis materials were observed in position. The patient is being followed up with the oral and maxillofacial surgery team.

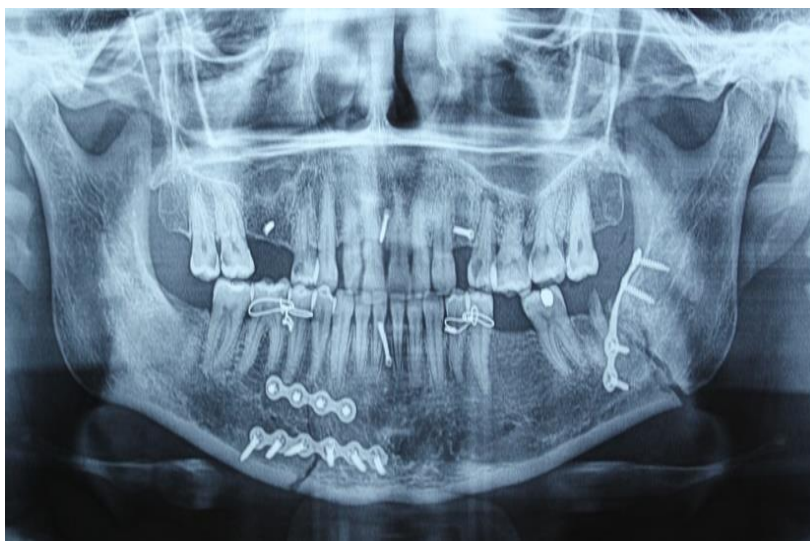


Figure 6. Postoperative panoramic radiograph (30 days).
Source: The authors.

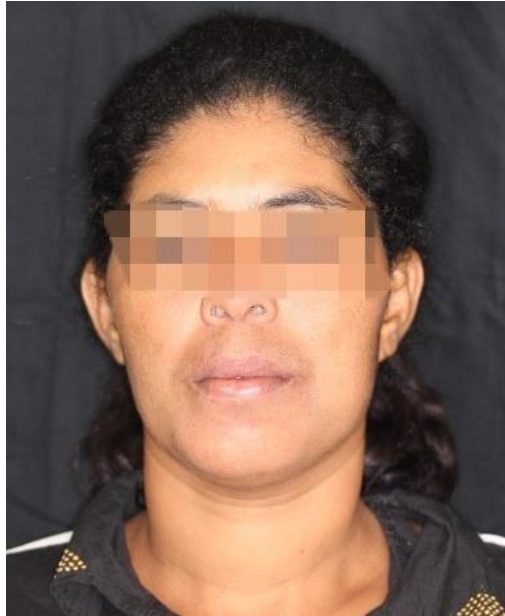

Figure 7. Postoperative frontal view.
Source: The authors.

DISCUSSION

Facial injuries and wounds are a frequent reality in emergency services (Scannavino, Santos, Novo & Novo, 2013). In order to treat them in a way that allows the best aesthetic and functional rehabilitation, the presence of a professional who has knowledge of the incidence and the etiology of facial fractures is essential for the professionals involved in the treatment and the patients, as in the case reported, where the patient was completely rehabilitated without complications and aesthetic defects by the specialized team. Within this context, Oral and Maxillofacial Surgery and Traumatology is increasingly established as a specialty of great importance present in hospital emergencies in the treatment of trauma patients from their reception until the end of the treatment process (Leite Segundo, Gomes, Campos & Falcão, 2004).

Trauma to the face stands out for its peculiar importance, as it has functional and emotional repercussions and the likelihood of permanent aesthetic deformities (Pereira et al., 2019), which becomes a major problem since the face is an area of high visibility for humans and permanent deformity can generate emotional damage and social stigma.

Surgical treatment of facial fractures aims to restore the function, aesthetics and anatomy of the region with the aid of miniplates and metallic structures for this purpose (Rodrigues et al., 2018). Due to the face being a highly visible region, whenever possible, as in this study, we can choose the intraoral access as the access of choice, as it can bring advantages such as the aesthetic quality, since it is not possible to observe external scars, and it has a lower complication rate (Carvalho, 2008).

The most common signs and symptoms associated with mandible fractures are limited mouth opening, edema, facial asymmetry, malocclusion, atypical mobility to manipulation, crepitus, paresthesia and pain (Rodrigues et al., 2018). In the described case, the patient had all these aspects, in addition to an extensive submandibular hematoma, which revealed the need for surgical repair of the fracture in question, which, if not performed, could lead to inadequate consolidation of the bone stumps, leading to a permanent deformity in the patient's occlusion and facial asymmetry, apart from the great chance of contamination and subsequent infection of the fractured area.

A variety of techniques have been used for internal fixation of mandibular angle fractures, including osteosynthesis with steel wire, two plates (upper and lower edges), a reconstruction plate at the lower edge, and a 2.0mm miniplate at the upper edge. The choice of treatment modality will depend on the fracture pattern. For simple and slightly displaced fractures, as we could see in the case

reported here, the Champy study advocates the use of a miniplate on the upper edge as sufficient for the treatment, reducing the complication rates of surgery, a technique which is considered simplified, with economy of surgical time and costs: factors that contributed to the choice of this technique in the present study. However, patients who show comminuted fractures, with great displacement and extensive soft tissue injury, it is not considered an adequate technique, and the AO/ ASIF philosophy should be used (Rodrigues, Castro, Melo, Farias & Brito, 2021).

The dental surgeon, faced with a situation of violence against women, can act by recognizing the signs of aggression or treating the injuries resulting from it. In the present study, the oral and maxillofacial surgery team was present in both forms of action. In both situations, there are rules and laws that determine the professional action to be taken, with conviction for anyone who is omitted. Mandatory notification must be carried out, professional secrecy must be maintained and a record of the injuries observed and the care performed must have (Vilella, 2019).

The prevalence of facial injuries caused by violence against women has high rates. Chaves et al. (2018) report in their work that international studies have found varying prevalence between 24.4% and 81.0% and that, in Brazil, the prevalence of maxillofacial trauma caused by violence in women was between 26.3% and 63.2%.

According to Hashemi & Beshkar (2011), in their study, most cases of maxillofacial fractures resulted from violence and the victims were women injured by an intimate partner. Chaves et al. (2018) state that in Brazil 70% of incidents take place indoors, where the criminal is the victim's husband or partner, corroborating our study where the aggressor was the victim's husband and was the causer of facial injuries.

Also, in the study by Hashemi & Beshkar (2011), domestic violence was the cause of fracture among 3.5% of patients and all victims were women, who comprised 13% of all women present in the study with a mean age of 33,8 years and the mandible fracture is the most common (38%), which can be explained by its prominence in the facial region.

In the studies of Chaves et al. (2018) and Rezende et al. (2007), the most common type of injury was only soft tissue injuries. The types of oral and maxillofacial injuries most mentioned in the reports by Garcez et al. (2019) were: excoriation (39.91%), ecchymosis (33.49%), blunt wound (27.31%) and edema (23.22%) and the middle third of the face was the most affected, unlike our study where the victim had a complex mandible fracture, which can be considered a more difficult injury to occur than a soft tissue injury, due to the need for a greater impact trauma to cause this condition.

CONCLUSION

Domestic violence is a great etiological agent of facial injuries for women victims of this situation. The presence of the oral and maxillofacial surgery team in hospital emergencies is of paramount importance for the correct diagnosis of facial injuries and their repair, allowing a good aesthetic-functional rehabilitation of patients in situation of vulnerability due to domestic violence.

REFERENCES

- Araújo, A. M. R. D. (2012). *Lesões no complexo maxilo-mandibular em mulheres que sofreram violência doméstica*. Monografia (Graduação em Odontologia) – Universidade Tiradentes. Aracajú, SE.
- Barros, M. A. N., Teslenko, V. B., Reis, G. N., Pancini, E. F., Pelissaro, G. S., & Cavalcanti, H. de A. (2021). Tratamento cirúrgico de uma fratura cominutiva de mandíbula com fixação interna rígida. *Archives of Health Investigation*, 10(8), pp. 1257–1259. <https://doi.org/10.21270/archi.v10i8.5217>

- Boffano, P., Kommers, S. C., Karagozoglu, K. H., Gallesio, C., & Forouzanfar, T. (2015). Mandibular trauma: a two-centre study. *Internacional Journal of Oral Maxillofacial Surgery*, 44(8), pp. 1-7.
- Carvalho Neto, M. F. (2008). Tratamento das fraturas mandibulares com fixação interna rígida: estudo comparativo entre via de acesso extraoral e intraoral com uso de trocarte percutâneo. *Revista Brasileira de Cirurgia Craniomaxilofacial*, 11(4), pp. 132-141.
- Chaves, A., Guerra Lund, R., Martos, J., Salas, M., & Soares, M. (2018). Prevalência de traumatismos maxilofaciais causados por agressão ou violência física em mulheres adultas e os fatores associados: uma revisão de literatura. *Revista da Faculdade de Odontologia - UPF*, 23(1). <https://doi.org/10.5335/rfo.v23i1.8081>
- Gadicherla, S., Sasikumar, P., Gill, S. S., Bhagania, M., Kamath, A. T., Pentapati, K. C. (2016). Mandibular fractures and associated factors at a tertiary care hospital. *Archives of Trauma Research*, 5(4), pp. 0-4.
- Garcez, R. H. M., Thomaz, E. B. A. F., Marques, R. C., Azevedo, J. A. P., & Lopes, F. F. (2019). Caracterização de lesões bucomaxilofaciais decorrentes de agressão física: diferenças entre gênero. *Ciência e Saúde Coletiva*, 24(3), pp. 1143-1152.
- Hashemi, H. M., & Beshkar, M. (2011). The prevalence of maxillofacial fractures due to domestic violence – a retrospective study in a hospital in Tehran. *Dental Traumatology*, 27, pp. 385-388.
- Leite Segundo, A. V., Gomes, V. D. R. L., Campos, M. V. S., & Falcão, M. F. L. (2004). Epidemiological study of the 261 facial fractures admitted on hospital regional of agreste/Caruaru - PE. *Odontologia Clínico-científica*, 3(2), pp. 117-122.
- Munante-Cardenas, J. L., Nunes, P. H. F., & Passeri, L. A. (2015). Etiology, treatment, and complications of mandibular fractures. *Journal of Craniofacial Surgery*, 26(3), pp. 611-615.
- Pereira, J. B., Rodrigues, D. C., Blois, M. C., & Souza, F. A. (2019). Trauma bucomaxilofacial resultado da violência doméstica contra mulher. *Revista Uningá*, 56(S3), pp. 169-179.
- Rezende, E. J. C., Araújo, T. M., Moraes, M. A. S., Santana, J. S. S., & Radicchi, R. (2007). Lesões buco-dentais em mulheres em situação de violência: um estudo piloto de casos periciados no IML de Belo Horizonte, MG. *Revista Brasileira de Epidemiologia*, 10(2), pp. 202-214.
- Rodrigues, E. D. R., Castro, C. C. L. P., Melo, T. M, Farias, A. L. C, & Brito, L. S. Jr. (2021). Fratura de mandíbula tratada através da técnica de champy: relato de caso. *Archives of Health Investigation*, 10(3), pp. 431-435.
- Rodrigues, R. D., Quintas P. H., Barreto, L. S., Costa, C. F. B., Silva, L. O. R., & Aguiar, J. F. (2018). Manejo cirúrgico de fratura de mandíbula: relato de caso. *Revista da Faculdade de Odontologia de Porto Alegre*, 23(3), pp. 343-347.
- Scannavino, F. L. F., Santos, F. S., Novo Neto, J. P., & Novo, L. P. (2013). Análise epidemiológica dos traumas bucomaxilofaciais de um serviço de emergência. *Revista de Cirurgia e Traumatologia buco-maxilo-facial*, 13(4), pp. 95-100.
- Villela, M. (2019). *Casos de violência contra a mulher com lesões em face: revisão de literatura e avaliação de dados*. Monografia (Graduação em Odontologia) – Faculdade de Odontologia da Faculdade Federal de Uberlândia. Uberlândia, Brasil.